Increased Functional Connectivity in Paediatric Traumatic Brain Injury:

Compensation or Artefact?

Nick Parsons[1], Govinda Poudel[2], Juan F. Dominguez D.[1], Matthew Hughes[3], Xiaoyun Liang[2], Karen Caeyenberghs[1]

[1.] Cognitive Neuroscience Unit, Deakin University, [2.] Mary Mackillop Institute for Health Research, Australian Catholic University, [3.] Swinburne University

@nick_parsons_

The Problem

- Young patients with TBI suffer from several symptoms including cognitive deficits and motor disorders[1]. These structural injuries may invoke functional reorganisation; however, this mechanism is still unclear.
- The majority of neuroimaging studies in paediatric TBI have focused on one MRI measurement only. In the present study, we utilised multiple fMRI measurements to thoroughly validate functional connectivity alterations in paediatric TBI.

The Sample

- 14 children with TBI (mean age 13.9 years ±3 years) were compared with an age-matched control group of 18 children. Each participant underwent a T1-weighted anatomical and resting-state functional MRI scan.

"Garbage in, Garbage out"

- Using single-subject manual independent component analysis, high and low frequency artefact were removed from fMRI data. Data then underwent pre-processing and denoising steps using FSL[2], ANTs[2], SPM[3], and Conn Toolbox[4]. Multiple fMRI measurements were used to cross-validate findings using a T1-weighted anatomical scan and resting-state fMRI scans.
- Regions of interest (ROI) within the default mode network included the medial prefrontal, posterior cingulate (PCC) and bilateral lateral parietal cortices (LP), and bilateral anterior middle temporal gyri. BOLD time-series information from three ROI clusters (PCC, LPr, LPl) were plotted for inspection using MATLAB.

Fig. 1 *Single-subject manual ICA signal/artefact decision tree*[5]

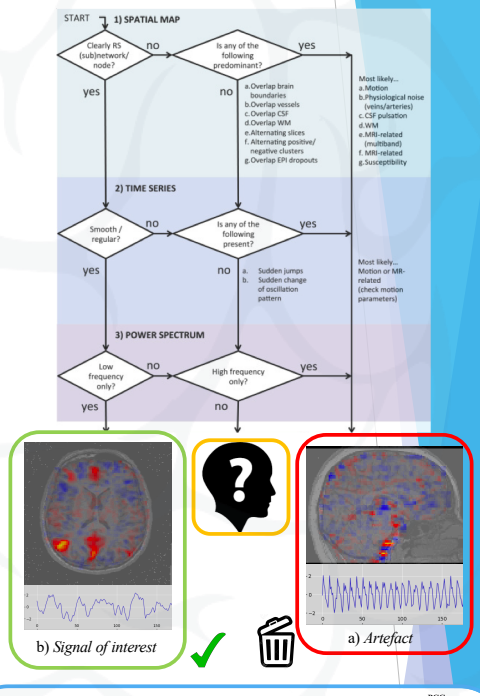

Fig 2. Increased functional connectivity in TBI

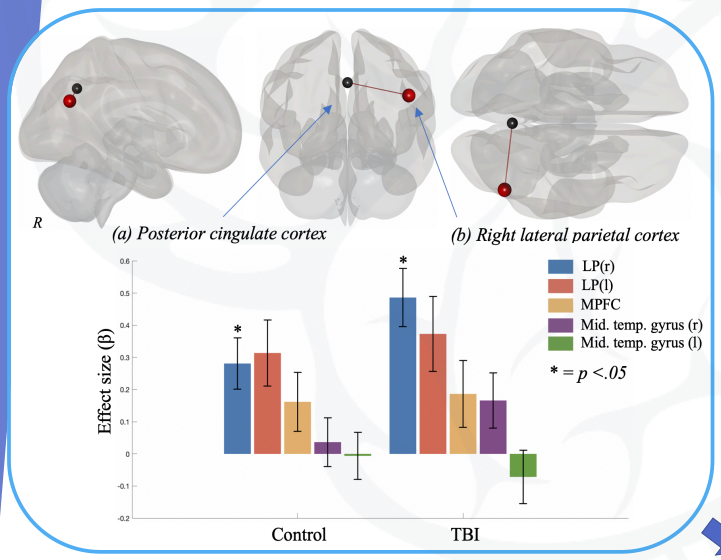

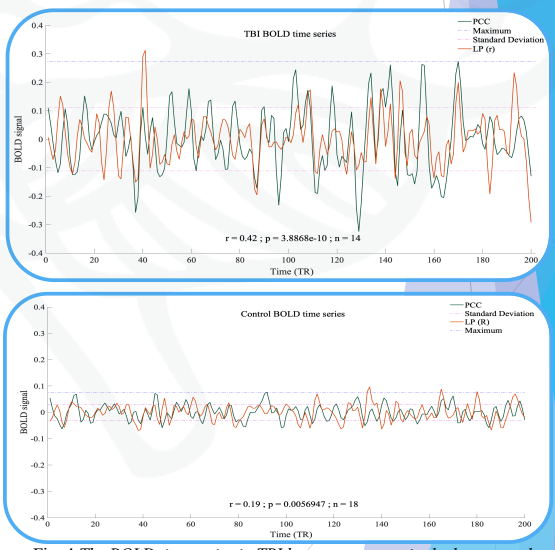

Fig. 4 *The BOLD time series in TBI has greater magnitude than controls*

Fig 3. Are group level networks homogenous?

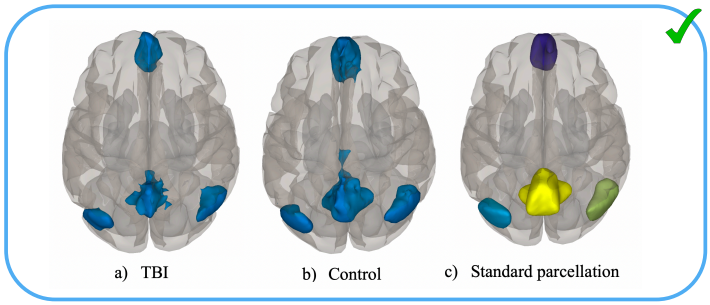

The Results

- A seed - ROI group contrast showed increased functional connectivity (t = 2.83, p = .05, FDR corrected) between the posterior cingulate cortex and the right lateral parietal cortex within the default mode network in the paediatric TBI group relative to controls. Although not significant, all other DMN regions also showed increased FC in the TBI group, suggesting the entire network is up-regulating.
- Group ICA revealed no gross alteration of the default mode network in either group compared to standard atlas ROI, warranting the use of a standard parcellation scheme (see fig 3).
- In TBI, the mean time series within the precuneus and bilateral lateral parietal cortices showed increased time-series amplitude, in both seed and target ROI.

The Meaning

- Our finding of increased unilateral functional connectivity suggests the brain is compensating for structural injury, both in term of functional connectivity and metabolic demand. These findings warrants further investigation using structural MRI techniques as to whether this correlates with reduced structural connectivity. Our further analyses will utilize a novel multilayer network analysis to capture structural-functional relationship directly. A clearer understanding of functional reorganisation may allow clinicians to provide more effective treatment programs for people with TBI.

References

1. Dennis, E., Babikian, T., Giza, C., Thompson, P. and Asarnow, R. (2018). Neuroimaging of the Injured Pediatric Brain: Methods and New Lessons. *The Neuroscientist*, 24(6), pp.652-670.
2. Jenkinson, M., Beckmann, C., Behrens, T., Woolrich, M. and Smith, S. (2012). FSL. *NeuroImage*, 62(2), pp.782-790.
3. Avants, B. B, Tustison, N., Song, G and Gee, J. ANTS: Advanced Open-Source Normalization Tools for Neuroanatomy. Penn Image Computing and Science Laboratory, 2009.
4. Friston, K., Holmes, A., Worsley, K., Poline, J., Frith, C. and Frackowiak, R. (1994). Statistical parametric maps in functional imaging: A general linear approach. *Human Brain Mapping*, 2(4), pp.189-210.
5. Griffanti, L., Douaud, G., Bijsterbosch, J., Evangelisti, S., Alfaro-Almagro, F., Glasser, M., Duff, E., Fitzgibbon, S., Westphal, R., Carone, D., Beckmann, C. and Smith, S. (2017). Hand classification of fMRI ICA noise components. *NeuroImage*, 154, pp.188-205.
6. Whitfield-Gabrieli, S., Nieto-Castanon, A., 2012. Conn: a functional connectivity toolbox for correlated and anticorrelated brain networks. Brain Connect. 2, 125-141.