2021 Best Research Poster Award

Barwon Health

DEAKIN UNIVERSITY

Localisation of diabetic retinopathy elements in retinal photographs

Student: Tim Murphy
Project Team Members: Dr. Amanda Douglass, Prof. James Armitage, A/Prof. Larry Abel

INTRODUCTION

Diabetes affects around 7.3% of the Australian adult population (1). Diabetic changes in the eye, known as diabetic retinopathy, can be sight threatening. This presents as different lesions: microaneurysms, haemorrhages, exudates, and cotton wool spots. It is therefore important that images for screening are appropriately inspected to determine severity, which is based on the type and number lesions identified. Screening requires intense scrutiny of the entire image as lesion location patterns are not well characterised, and in mild cases the lesions can be subtle.

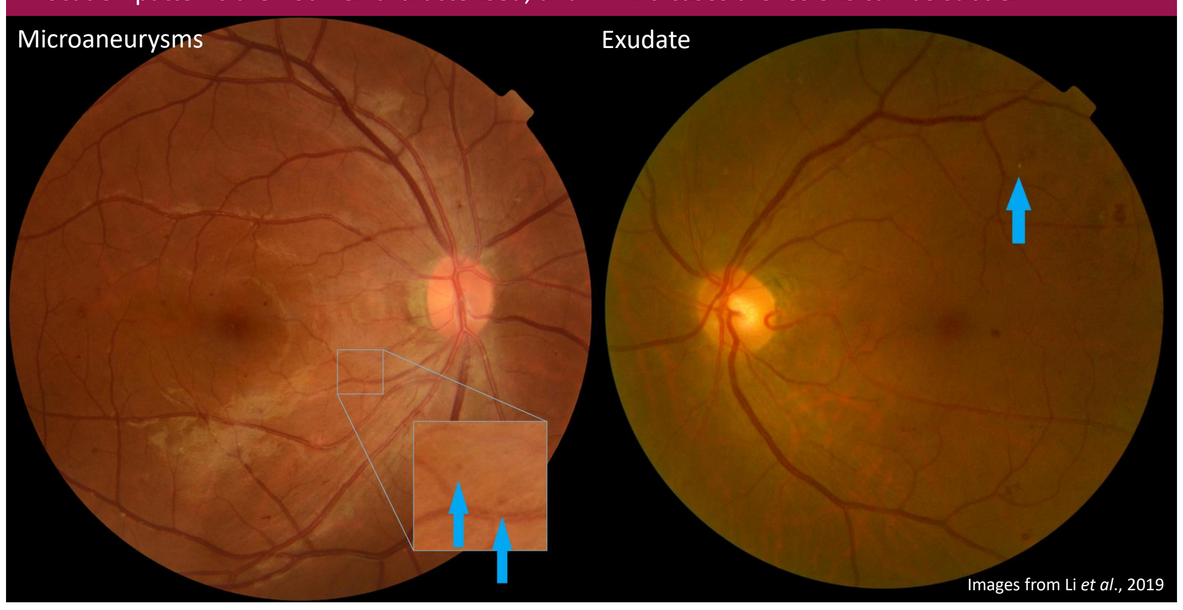

Images from Li *et al.*, 2019

OBJECTIVES

- Determine whether parts of the retina are more susceptible to different diabetic retinopathy pathology; and
- Determine the anatomical correlates of various features of diabetic retinopathy.

METHOD

Three publicly available datasets of annotated retinal photographs were obtained (2-4), containing a combined 757 images of diabetic retinopathy and 70 images of retinal vasculature. Each image is paired with annotation data, describing the location and type of lesion or vessel.

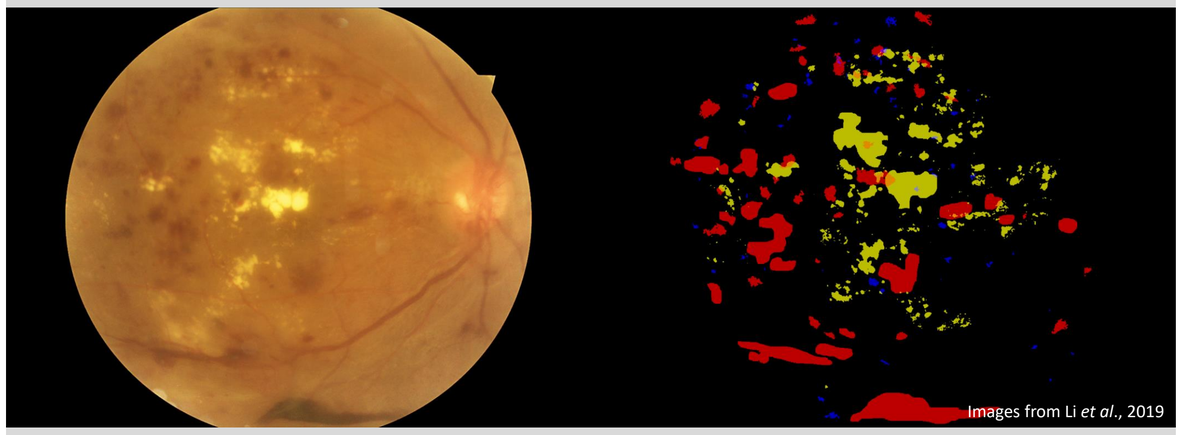

Images from Li *et al.*, 2019

- Images corrected for centration, rotation, and field of view.
- Vessel and lesion locations extracted and collated into a frequency matrix.
- Heatmaps generated showing frequency distribution of arterioles, venules, microaneurysms, haemorrhages, exudates, and cotton wool spots.
- Heatmaps converted into binary masks using thresholding and convolution filtering.

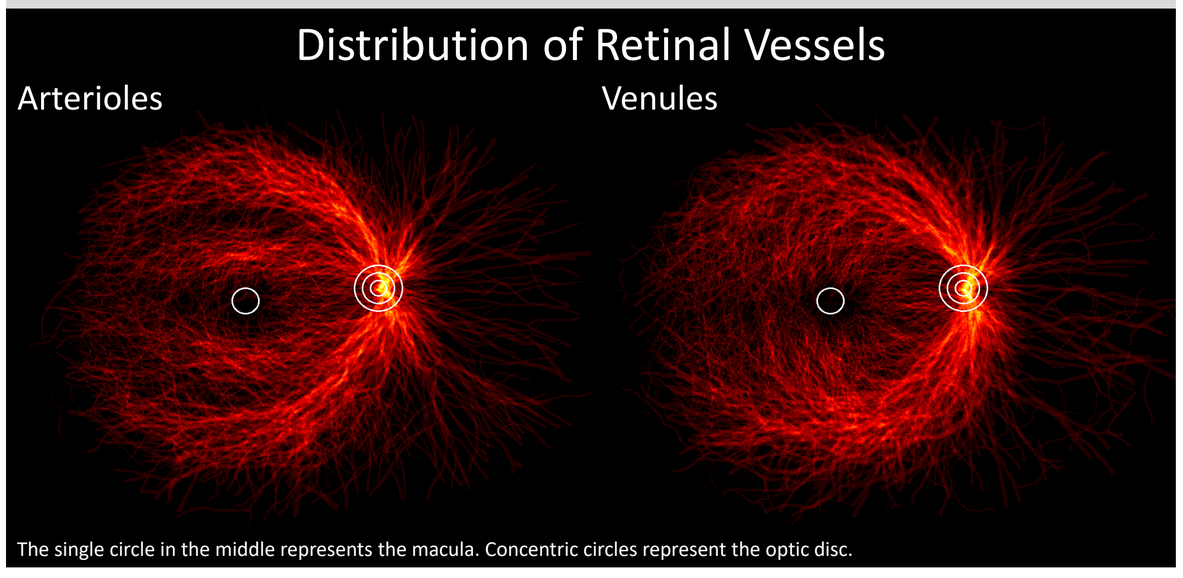

The single circle in the middle represents the macula. Concentric circles represent the optic disc.

REFERENCES

1. International Disease Foundation (2019) *IDF Diabetes Atlas, 9th edn.* 9th edn. Brussels, Belgium: International Diabetes Federation,. Available at: https://www.diabetesatlas.org.
2. Li, T. *et al.* (2019) 'Diagnostic assessment of deep learning algorithms for diabetic retinopathy screening', *Information Sciences*, 501, pp. 511–522.
3. Abbasi-Sureshjani, S. *et al.* (2015) 'Biologically-Inspired Supervised Vasculature Segmentation in SLO Retinal Fundus Images BT - Image Analysis and Recognition', in Kamel, M. and Campilho, A. (eds). Cham: Springer International Publishing, pp. 325–334.
4. Hu, Q., Abràmoff, M. D. and Garvin, M. K. (2013) 'Automated separation of binary overlapping trees in low-contrast color retinal images.', *Medical image computing and computer-assisted intervention : MICCAI ... International Conference on Medical Image Computing and Computer-Assisted Intervention*, 16(Pt 2), pp. 436–443.

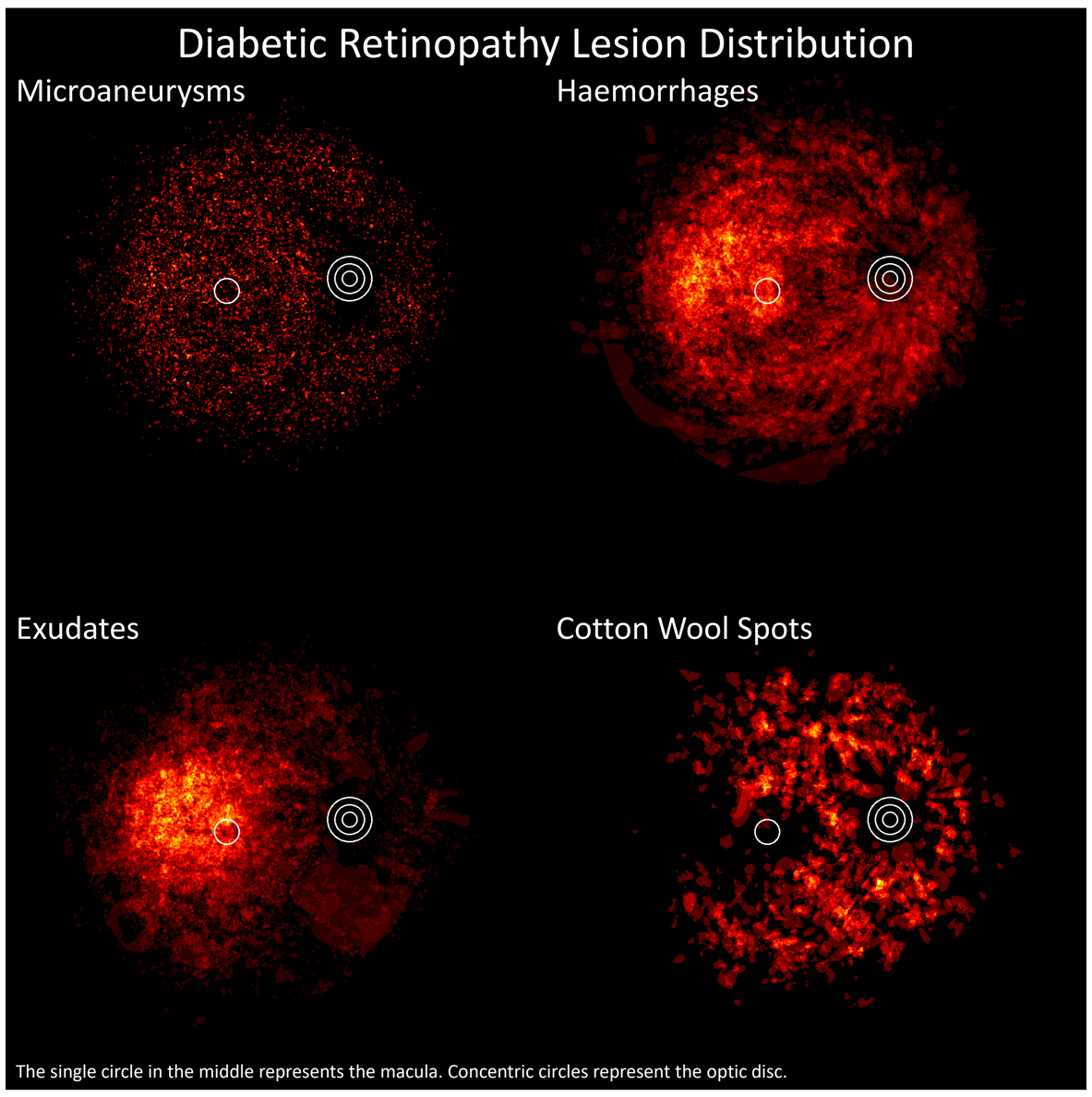

The single circle in the middle represents the macula. Concentric circles represent the optic disc.

RESULTS

- Arteriole and venule patterns: two arcs for arterioles, one for venules.
- Microaneurysms and haemorrhages occur in all retinal locations.
- Exudates frequently occur in a region temporal to the macula, which correlates with decreased venule density.
- Cotton wool spots rarely seen in region temporal to macula.
- 15% of exudate mask overlaps with cotton wool spot mask.
- 27% of exudate mask overlaps with venule mask.



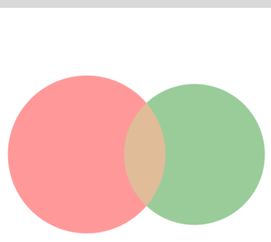





DISCUSSION

Clear patterns emerged regarding blood vessel and some diabetic retinopathy locations, especially exudates and cotton wool spots. While the underlying pathophysiology for these patterns need further characterisation, these results indicate that the region immediately temporal to the macula is more susceptible to diabetic retinopathy in general, especially exudates. Conversely, cotton wool spots and exudates occur most commonly in separate retinal locations, which may aid clinicians in differentiating between the two. These results suggest that trainee clinicians may be more likely to notice and correctly characterise diabetic retinopathy if the direct their attention towards linking the area of the retina being inspected and the characteristic pathological features that may be found.

CONCLUSION

- Retinal arterioles and venules follow distinct patterns.
- Microaneurysms and haemorrhages occur throughout the eye.
- Exudates and cotton wool spots are found in particular regions with higher frequency.
- Possible segregation of exudates and cotton wool spots, and exudates and venules.
- Lesion distribution may be useful for directing visual attention.
- Further research is necessary to understand the underlying pathophysiology.